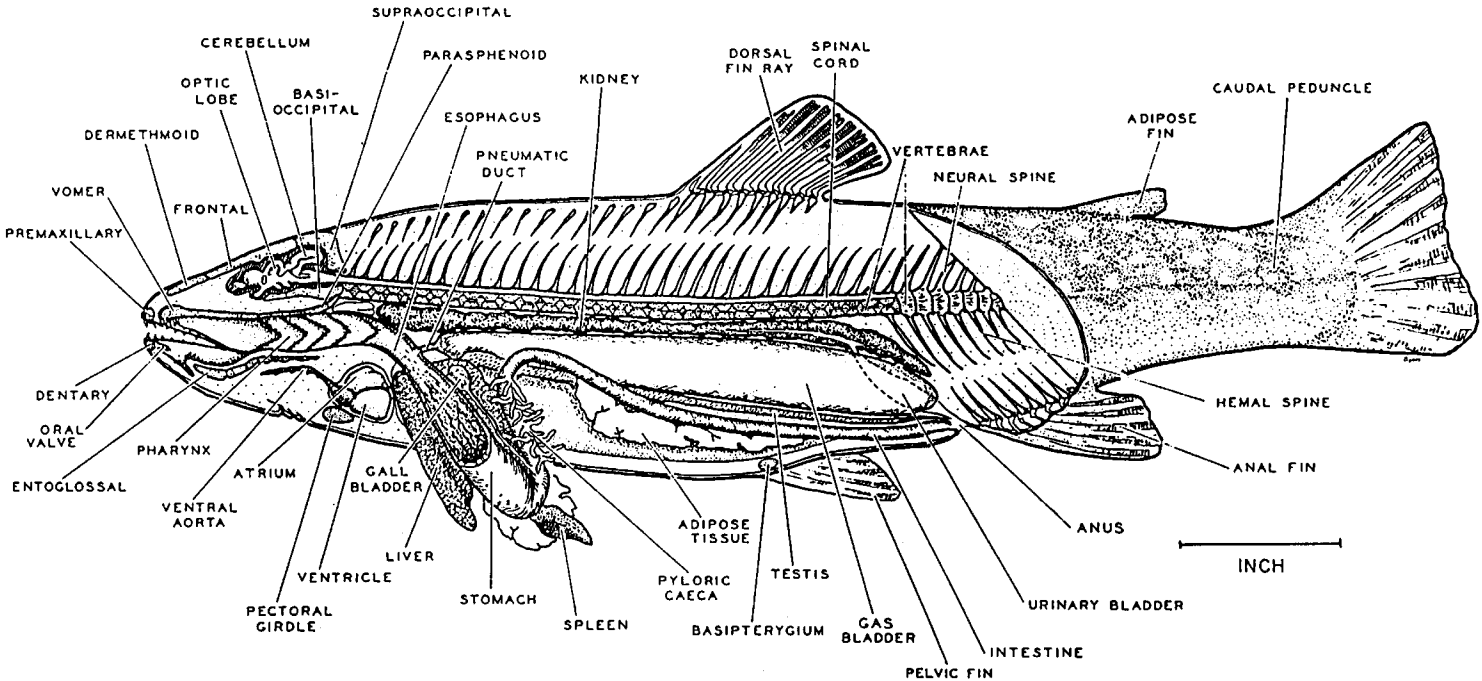

Anatomy of a soft-rayed bony fish, the brook trout, *Salvelinus fontinalis*. From Hunn (1988).